

A RARE OCCURRENCE OF CHOLECYSTOGASTRIC FISTULA MIMICKING PERFORATED PEPTIC ULCER SYMPTOMS

Hossein Torabi¹, Kasra Shirini², Dorsa Shirini³, Rona Ghaffari¹, Siavosh Katebi²

¹Department of General Surgery, Poursina Medical and Educational Center, Guilan University of Medical Sciences, Rasht, Iran

²Department of General Surgery, Iran University of Medical Science, Tehran, Iran

³Cardiovascular Research Center, Shahid Beheshti University of Medical Sciences, Tehran, Iran

CASE REPORT

Doi: 10.33695/rojes.v4i2.65
Accepted: 22.12.2022

Abstract

Cholecystogastric fistula is one of the rarest and most life-threatening complications of gallbladder stone disease. This disease can mimic other diseases such as perforated peptic ulcers and is too hard to be diagnosed preoperatively. This article presents a patient with cholecystogastric fistula presentation as a peptic ulcer disease. This article presents a 58-year-old man with the presentation of abdominal pain and acute cholecystitis symptoms mimicking perforated peptic ulcer during hospitalization. Clinical examination and imaging confirmed the diagnosis of peptic ulcer disease. Laparotomy revealed that the disease was a simultaneous gallbladder stone disease, which led to acute cholecystitis and following cholecystogastric fistula. Cholecystogastric fistula should be considered a significant differential diagnosis in patients with abdominal pain and cholecystitis symptoms.

Corresponding author:
Kasra Shirini
kasrashirini21@gmail.com

Keywords: cholecystogastric fistula, cholecystoenteric fistula, cholecystitis, bile duct, abdominal pain

Introduction

The prevalence of gallstones worldwide varies between 5 % to 25 % [1]. In Iran, the prevalence of this disease is approximately 1.1 % in male patients and 12.8% in female patients between 50 and 60 years old, which is highly increased by aging [2]. The gallbladder can cause different problems and one of the most common and important problems, which can lead to surgical intervention, is acute cholecystitis [3]. On the other hand, this disease can cause rare but health hazards, such as cholecystoenteric fistula, an abnormal connection between the gallbladder and stomach [1]. Because of its very nonspecific

symptoms that can be confused with other conditions such as a perforated peptic ulcer or just single acute cholecystitis, it is often diagnosed during surgery (92.1%) [4]. Studies have shown that the prevalence of fistula between gallbladder and other organs depends on its location, and the prevalence of cholecystogastric fistula is less than others, approximately just 2% [1,5].

The main way to treat and eradicate cholecystogastric fistula, which is a life-threatening problem, is surgery. But choosing the surgical methods such as open or laparoscopy or endoscopic surgery depends on various factors such as the patient's condition

and possible diagnosis that the surgical team considers for the patient [1,6,7].

In this study, a 58-year-old man was presented with acute cholecystitis and cholecystogastric fistula symptoms with a clinical presentation mimicking acute cholecystitis and perforated peptic ulcer.

Case presentation

A 58-year-old male presented to the surgical Department of Poursina Hospital Medical Center, in Rasht, Iran, in November 2021, with a four-day history of severe generalized abdominal pain with a predominance of the epigastric and right upper quadrant (RUQ) area of the abdomen with the radiation to the patient's back and right shoulder. The pain started suddenly and increased dramatically. The patient claimed that a day before coming to the hospital, he had vomited three or four times, containing food, and he claimed that there was no blood; the pain increased by feeding, but it had nothing to do with defecation and gas-passing. The patient claimed that he did not have any defecation since two days before he came to the hospital, but he said that he had gas-passing. He also mentioned that he had an intermittent low-grade fever and the highest degree recorded by him was 38.5 degrees Celsius. It did not decrease after using medication such as acetaminophen tablet 500 mg.

More investigation revealed that the patient had diabetes three years ago, and metformin was prescribed. However, he did not take any medicine and arbitrarily stopped taking them six months after starting medication. The patient had a low-grade fever (38 degrees Celsius) at the time of admission, but other vital signs were normal.

On abdominal examination, the patient had moderate generalized tenderness with a predominance of RUQ and epigastric area, but distention and gardening were not detected during the abdominal examination.

He was asked to do an upright chest X-ray and an upright abdominal X-ray due to suspicion of peritonitis. He also was asked to do abdominal ultrasonography due to suspicion of acute cholecystitis. The ultrasonography reports represented the gallbladder with dimensions of 83x35 mm and increased wall thickness is about 5 mm, and the existence of 2 gallstones measuring 24 mm and 10 mm. On the other hand, in the patient's chest and abdominal X-ray, a suspicious air level was seen below the right side of the diaphragm, as can be seen in Figure 1.

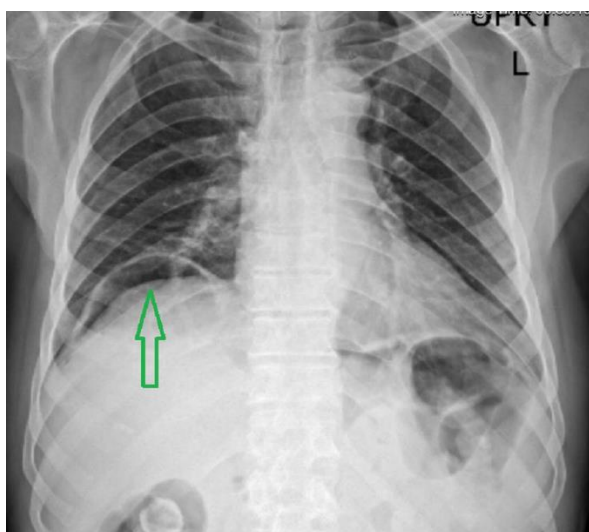


Figure 1 - Upright chest X-ray: The green arrow shows the suspicious free air level

The blood test analyzed presented a high level of erythrocyte sedimentation rate (ESR)=93 (usually should be under 15 in males), C-reactive protein (CRP) = 200 (usually should be under 5 in adults), and leukocytosis (white blood cells [WBC] = 15700 g/dL with a neutrophilia ratio of 68%), Amylase = 588 (usually should be under 95 in adults), Fecal occult blood test were positive, Lipase =20 (usually should be under 60 in adults), and hemoglobin (Hb) = 9.8 g/dL (usually should be between 12 -14 in adult males).

According to the patient's clinical presentation and our investigations, such as

ultrasonography, chest and abdominal X-ray, and blood test results analysis, two main diagnoses were made: suspicion of peritonitis caused by perforated peptic ulcer and acute cholecystitis.

Due to the patient's deteriorating condition, such as progress to severe and generalized abdominal tenderness and RUQ and epigastric rebound tenderness and sudden metabolic acidosis appeared in patients arterial blood gas (ABG) result, surgeons suspecting peritonitis caused by perforated peptic ulcer decided to perform an emergency laparotomy, instead of asking the patient for abdominal computed tomography (CT) scan or preparing an endoscopy procedure. Perforated peptic ulcers followed by peritonitis can be life-threatening, so it should be considered the first and most important diagnosis to save the patient's life.

A midline incision was made for the patient's abdomen. The gallbladder was found to be severely inflamed. A small amount of debridement and free fluid was seen around the gallbladder near the stomach. After resection of the adhesion between the infundibulum part of the gallbladder and the stomach, a perforated wound measuring 1x1 cm was seen in the prepyloric area of the stomach exactly in the posterior part of the gallbladder, as can be seen in Figure 2.

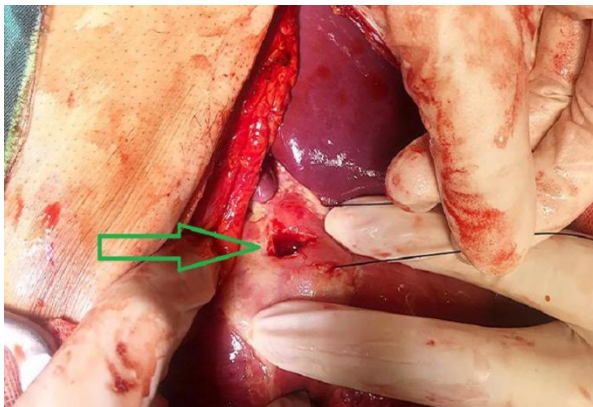


Figure 2 - Perforated peptic ulcer: The green arrow shows the perforation which is located in the prepyloric area of the stomach

A cholecystogastric fistula was also seen between the gallbladder and the stomach wall, from which gastric secretions exuded. Due to two large gallstones in the gallbladder, the patient underwent cholecystectomy. The gallbladder after resection can be seen in Figure 3.

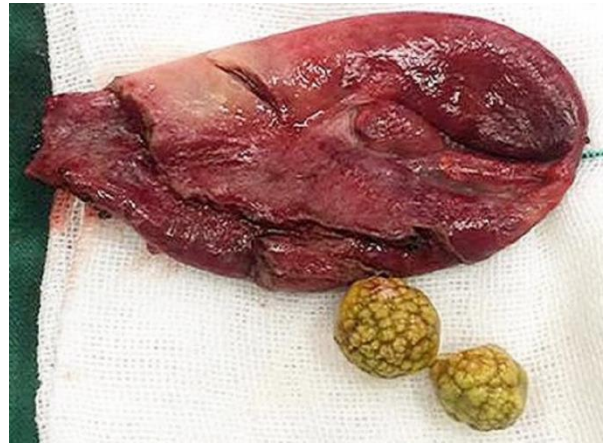

Figure 3 - The gallbladder and its gallstones after resection

The wound in the prepyloric area of the stomach wall was repaired by wedge resection, and a biopsy was prepared and sent to the laboratory for more investigation. The abdominal cavity was washed with normal saline serum, and a drain was inserted for the patient. The patient's stomach was partially closed.

On a postoperative day one, his vital signs were within normal limits. Due to the infection in the abdominal cavity, the patient was treated with the injected metronidazole and ceftriaxone during hospitalization. The patient's skin was finally wholly closed with a delay of one week and relative treatments of the patient's infection.

After the second surgery on postoperative day 5, he was discharged. Eventually, the postoperative histopathology report was unrevealing.

Discussions

This article presented an acute cholecystitis case with cholecystogastric fistula, which occurred in a 58-year-old man, mimicking perforated peptic ulcer. Gallbladder stone disease is seen worldwide, including in Iran [2].

One of the most common reasons that can lead to cholecystitis is gallbladder stone. Cholecystogastric fistula is a rare and health-threatening complication of cholecystitis [1,8].

The probability of fistula occurring between the gallbladder and different parts of the gastrointestinal tract is different and depends on their location. The most common of them is cholecystoduodenal fistula with the prevalence of 77%-90%, and the rarest of them is cholecystogastric fistula with the probability of 2% [5,8,9]. Although, because of development occurred in computed tomography (CT) scan technology and endoscopic techniques and technology, it is much easier for surgeons to diagnosis cholecystoenteric fistula such as cholecystogastric fistula preoperatively, it is still too hard to diagnose this disease preoperatively because it does not have any specific symptoms compared with cholecystitis [7].

The main way to treat this disease is surgery. However, there are different surgical methods, such as open surgery, laparoscopic surgery, and endoscopic surgery; the consideration of the most appropriate method is based on the patient's condition and surgical team decision and consideration [1,7,10].

In this case, the patient was initially scheduled to undergo an abdominal CT scan after the investigations. However, due to the patient's clinical condition, such as metabolic acidosis, which appeared suddenly in the patient's blood test results and was not in the patient's previous test, and the rebound tenderness that became generalized and intensified and expanded, the patient underwent laparotomy.

Various studies have been performed on the types of cholecystoenteric fistula, its diagnosis, and its treatment methods [1,6,7,8]. However, given the rarity of this disease, and the fact that it can be life-threatening and that it can be confused with other dangerous diseases such as perforated peptic ulcer, which are also life-threatening, the diagnosis and choosing the right and the most appropriate treatment method, which is based on patient's clinical condition and clinical findings, is crucial.

Conclusion

Cholecystogastric fistula is a type of cholecystoenteric fistula that occurs very rarely and is one of the most important and life-threatening complications of gallbladder stone disease. Unfortunately, it is too hard to diagnosis this disease preoperatively, and it can mimic other health hazard diseases such as a perforated peptic ulcer. Therefore, it is crucial to consider this disease in patients who presented to the hospital with abdominal pain and symptoms of cholecystitis to diagnose it and select the most appropriate treatment methods.

References

- [1] A Aamery, O Pujji, M Mirza: Operative management of cholecystogastric fistula: case report and literature review. *J Surg Case Rep.* 2019, 4:1-2. DOI:10.1093/jscr/rjz345
- [2] S Massarrat: Prevalence of gallstone disease in Iran. *J Gastroenterol Hepatol.* 2001, 16:564-567. DOI:10.1046/j.1440-1746.2001.02478.x
- [3] D Gandhi, V Ojili, P Nepal, et al.: A pictorial review of gall stones and its associated complications. *Clin Imag.* 2020, 60:228-236. DOI:10.1016/j.clinimag.2019.11.015
- [4] MF Ali, D Friedel, G Levin: Two Anomalies in One: A Rare Case of an Intrahepatic Gallbladder with a Cholecystogastric Fistula. *Case Rep Gastroenterol.* 2017, 21:148-154. DOI:10.1159/000462964

- [5] AP Duzgun, MM Ozmen, MV Ozer, F Coskun: Internal biliary fistula due to cholelithiasis: a single-centre experience. *World J Gastroenterol.* 2007, 13:4606-4609. DOI:10.3748/wjg.v13.i34.4606
- [6] M Saeed, M Khan, M Bachan, Z Khan: Cholecystogastric fistula: a rare complication of cholelithiasis/ascending cholangitis. *Chest.* 2019, 156:A2039-A2040. DOI:10.1016/j.chest.2019.08.1999
- [7] X Li, X Zhao, P Zheng, X-M Kao, X-S Xiang, W Ji: Laparoscopic management of cholecystoenteric fistula: A single-center experience. *Journal of International Medical Research.* 2017, 45:1090-1097. DOI:10.1177/0300060517699038
- [8] MR Boland, GA Bass, I Robertson, TN Walsh: Cholecystogastric fistula: a brief report and review of the literature. *Journal of Surgical Case Reports.* 2013, 28:1-3. DOI:10.1093/jscr/rjt028
- [9] D Arioli, I Venturini, M Masetti, et al.: Intermittent gastric outlet obstruction due to a gallstone migrated through a cholecysto-gastric fistula: a new variant of "Bouveret's syndrome". *World J Gastroenterol.* 2008, 7:125-128. DOI:10.3748/wjg.14.125
- [10] A Tarasconi, F Coccolini, WL Biffl, et al.: Perforated and bleeding peptic ulcer: WSES guidelines. *World J Emerg Surg.* 2020, 15:2020. DOI:10.1186/s13017-019-0283-9