

## EMERGENCY HYPOPHYSECTOMY FOR PITUITARY APOPLEXY IN A PREVIOUSLY UNDIAGNOSED CASE OF ACROMEGALY

Alexandra Ioana Trandafir<sup>1</sup>, Eugenia Petrova<sup>1,2</sup>, Adina Ghemigian<sup>1,2</sup>, Ana Valea<sup>3,4</sup>, Mara Carsote<sup>1,2</sup>, Florica Şandru<sup>2,4</sup>

1. "Constantin Ion Parhon" National Institute of Endocrinology, Bucharest, Romania
2. "Carol Davila" University of Medicine and Pharmacy, Bucharest, Romania
3. "Iuliu Hatieganu" University of Medicine and Pharmacy, Cluj-Napoca, Romania
4. Elias Emergency Hospital, Bucharest, Romania

---

### CASE REPORT

DOI: 10.33695/rojes.v3i2.45  
Accepted: 07.07.2021

### Abstract

Acromegaly is caused in majority of cases by a pituitary tumour, typically a macro-somatotropinoma. Pituitary apoplexy is a very rare event which requires prompt recognition and intervention. This complication represents an emergency because of the risk of panhypopituitarism, including adrenal insufficiency, optic chiasma anomalies and cranial nerves paresis, thus the pituitary surgical approach is needed in order to improve the prognostic. We aim to introduce an unusual case of pituitary apoplexy which started with headache on a previously asymptomatic young male adult, further on requiring hypophysectomy for the presence of somatotropinoma - related massive apoplexy. Imagistic and hystopathological examination diagnosed pituitary tumour apoplexy, a rare event that can explain laboratory findings such as moderately increased IGF1 with uncharacteristically normal GH levels in 24 hours GH profile. This illustrates the complex effects of pituitary tumour apoplexy. In addition, it is worth mentioning that following surgical treatment, IGF1 levels and glycaemic status normalized and no pituitary insufficiency was found at 3 months follow-up. Our patient's case emphasizes the importance of rare pathologies such as pituitary tumour apoplexy in the differential diagnosis of severe headache in young otherwise healthy patients. Overall, the decision of neurosurgery in adenoma – related apoplexy helps the recovery of pituitary function, and even optic chiasma or cranial nerves complications.

---

Corresponding author:  
Mara Carsote  
carsote\_m@hotmail.com

**Keywords:** hypophysectomy, pituitary apoplexy, acromegaly

---

### Introduction

Acromegaly is caused in majority of cases by a pituitary tumour, typically a macro-somatotropinoma [1]. The disease associates a higher risk of cardio-vascular events, glucose profile anomalies, some cancers, but also local

complications due to the tumours itself [2]. Pituitary apoplexy is a very rare event which requires prompt recognition and intervention [3]. This complication represents an emergency because of the risk of panhypopituitarism, including adrenal insufficiency, optic chiasma anomalies and

cranial nerves paresis, thus the pituitary surgical approach is needed in order to improve the prognostic. The larger tumour, the presence of other co-morbidities like diabetes mellitus might increase the risk of this unusual disease [4,5]. Some cases are treated conservatory, but most of them are considered an emergency, thus it is mandatory to rapidly address a neurosurgical approach [6]. Also, the conditions involve a medical emergency which is linked to the presence of pan-hypopituitarism, especially acute, secondary adrenal insufficiency [7].

We aim to introduce an unusual case of pituitary apoplexy which started with headache on a previously asymptomatic young male adult, further on requiring hypopysectomy for the presence of somatotropinoma - related massive apoplexy.

The patient agreed for anonymously presentation of his medical records from different hospitals.

### Case presentation

A 26 year-old male patient without previous medical history, or family history of any disease, presented to the Emergency Room for severe headache accompanied by nausea and emesis. The patient was hemodynamically and respiratory stable. No neurological deficits or diplopia were present. He was treated with non-opioid analgesics, with poor response. Emergent MRI (magnetic resonance imaging) without contrast was performed at emergency room and it detected a pituitary macroadenoma of 18.5/23/25 mm (millimetre). The patient was therefore referred for further investigation.

On admission in our Institute, clinical examination of the patient revealed blood pressure of 130/80 mmHg, body mass index BMI of 32.24 kg/m<sup>2</sup>. Physical appearance was acromegaly-like with prominent supraorbital ridge, broad nose, large lips, macroglossia, coarsening of facial features and enlarged

hands and feet. Photographic review suggested the onset of acromegalic features 5 years ago.

Laboratory evaluation revealed hepatic cytolysis and hypercholesterolemia (Table 1). Glycaemic status showed a fasting plasma glucose level of 146 mg/dL (normal range: 70-105) and glycosylated haemoglobin level of 10.4% (normal range: 4.8-5.9) (Table 1). The mean value of 24 hours GH (Growth Hormone) profile was 0.56 ng/mL and IGF1 (Insulin-like Growth Factor) was 393.3 ng/mL (normal range: 94-271) (Table 1,7).

Parameter	Value 1*	Value 2**	Normal	Units
Ionic calcium	3.92	NA	3.9-4.9	mg/dL
Total calcium	9.5	9.34	8.4-10.2	mg/dL
Serum phosphorus	<b>5.4</b>	3.81	2.3-4.7	mg/dL
fasting glycaemia	<b>146</b>	92.1	70-105	mg/dL
Glycosylated hemoglobin	<b>10.4</b>	5.2	4.8-5.9	%
Total cholesterol	<b>203</b>	159.3	0-200	mg/dL
Triglycerides	57	28.3	0-149	mg/dL
HDL-cholesterol	67	58.9	40-60	mg/dL
LDL-cholesterol	126	95	60-160	mg/dL
Magnesium	1.9	2.04	1.6-2.55	mg/dL
Sodium	138	143	136-145	mmol/L
Potassium	4.5	4.94	3.5-5.1	mmol/L
Chlorine	105	104.8	94-111	mmol/L
Total proteins	8.1	NA	6.4-8.3	g/dL
Urea	44	33.1	15-50	mg/dL
Creatinine	0.79	0.88	0.5-1.2	mg/dL
Uric acid	5.7	5.1	2.6-6	mg/dL

\*Preoperative - November 2021

\*\*Postoperative - March 2022

**Table 1 - The biochemistry panel before and 3 months after surgery**

High IGF1 in addition to facial features were consistent with the diagnostic of acromegaly. Thyroid evaluation showed a low T3 (triiodothyronine) level of 62.43 ng/mL (normal range: 80-200) with TSH (Thyroid Stimulating Hormone) of 0.64  $\mu$ UI/mL (normal range: 0.5-4.5) which is consistent with mild central hypothyroidism (Table 2).

The endocrine panel further showed hypogonadotropic hypogonadism, with level of total plasma testosterone of 0.81 ng/mL (normal ranges: 2.49-8.36) and LH (Luteinizing Hormone) level was 2.63 mIU/mL (normal ranges: 1.7-8.6) (Table 4), and low prolactin level of 3.18 ng/mL (normal ranges: 4.04-15.2) (Table 6). ACTH (Adrenocorticotropic Hormone) and cortisol levels were low normal (Table 5), but partial central adrenal insufficiency could not be ruled out considering that an ITT (insulin tolerance test) test could not be performed due to the clinical status and associated newly detected secondary diabetes mellitus. These anomalies are consistent with the diagnostic of hypopituitarism due to macroadenoma and associated apoplexy.

Parameter	Value 1*	Value 2**	Normal	Units
TSH	0.64	1.5	0.5-4.5	μUI/mL
FT4	10.7	11.95	9-19	pmol/l
T3	<b>62.43</b>	NA	80-200	ng/dL
Plasma calcitonin	<1	NA	5.17-9.82	pg/mL

\*Preoperative - November 2021

\*\*Postoperative - March 2022

**Table 2 - The thyroid hormonal panel before and 3 months after surgery**

Bone turnover marker CrossLaps was inhibited and bone formation marker osteocalcin was increased (Table 3). Hypovitaminosis D was also detected. Low bone mineral density for age and gender was not found on central DXA (Dual-Energy X0Ray Absorptiometry) examination (Table 9).

Parameter	Value 1*	Value 2**	Normal	Units
25-hydroxy-vitamin D	<b>14.4</b>	<b>25.3</b>	30-100	ng/mL
CrossLaps	<b>1.49</b>	NA	0.162-0.436	ng/mL
Osteocalcin	<b>55.65</b>	NA	11-43	ng/mL
Parathormone	49.56	NA	15-65	pg/mL

\*Preoperative - November 2021

\*\*Postoperative - March 2022

**Table 3 - Bone metabolism panel before and 3 months after surgery**

Parameter	Value 1*	Value 2**	Normal	Units
FSH	3.68	5.07	1.5-12.4	mIU/mL
LH	2.63	5.42	1.7-8.6	
Total plasma testosterone	<b>0.81</b>	2.68	2.49-8.36	ng/mL
Free testosterone	3.29		1-28.28	pg/mL

\*Preoperative - November 2021

\*\*Postoperative - March 2022

**Table 4 - Pituitary-gonadal axis hormonal panel before and 3 months after surgery**

Parameter	Value 1*	Value 2**	Normal	Units
ACTH	23.21	25.34	3-66	pg/mL
Morning plasma cortisol	11.34	12.94	4.82-19.5	μg/dL

\*Preoperative - November 2021

\*\*Postoperative - March 2022

**Table 5 - Pituitary-adrenal axis hormonal panel before and 3 months after surgery**

Parameter	Value 1*	Value 2**	Normal	Units
GH	0.534	0.06	0.02-6.88	ng/mL
IGF1	<b>393.3</b> (normal ranges: 94-271)	167.6 (normal ranges: 83-262)		ng/mL
PRL	<b>3.18</b>	7.17	4.04-15.2	ng/mL

\*Preoperative - November 2021

\*\*Postoperative - March 2022

**Table 6 - Pituitary-somatotropic axis hormonal panel before and 3 months after surgery**

IGF 1	November 2021	Units
Value 1	0.53	ng/mL
Value 2	0.74	ng/mL
Value 3	0.57	ng/mL
Value 4	0.4	ng/mL
24 hours profile	0.56	ng/mL

**Table 7 - GH profile/24 hours before surgery**

March 2022:-75 mg glucose per os is administered					
time(minutes)	0'	30'	60'	90'	120'
GH(ng/mL)	0.06	0.06	0.07	0.06	0.06
glucose (mg/dL)	78.1	183.4	186.8	160.1	95.4

**Table 8 - GH in OGTT 3 months after surgery**

IV (intravenous) contrast MRI detected an inhomogeneous pituitary tumour with haemorrhage and necrosis with maximum diameters of 15 mm (transverse) /12 mm

(cranio-caudal) /13 mm(antero-posterior) with particular imaging features that recommended neurosurgery (Figure 1).

Regions	BMD (g/cm <sup>2</sup> )	Z-score (SD)
L1-4	1.249	-0.4
femoral neck	1.015	-1
total hip	1.119	-0.3

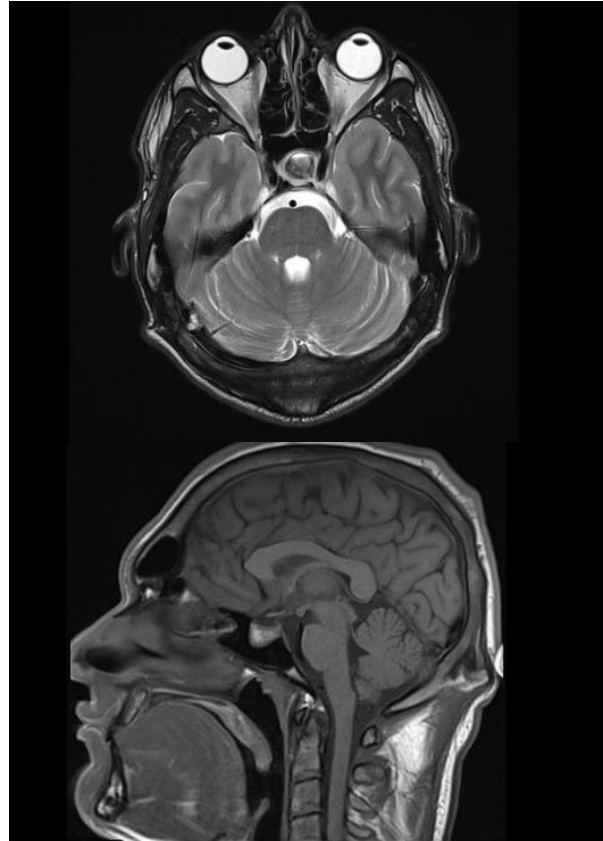
**Table 9 - DXA results (BMD=bone mineral density)**

Immunohistochemistry	
GH	positive
PRL	positive
FSH	negative
LH	negative
TSH	negative
ACTH	negative
Ki 67	positive 15%

**Table 10 - Immunohistochemistry assessment of pituitary adenoma**

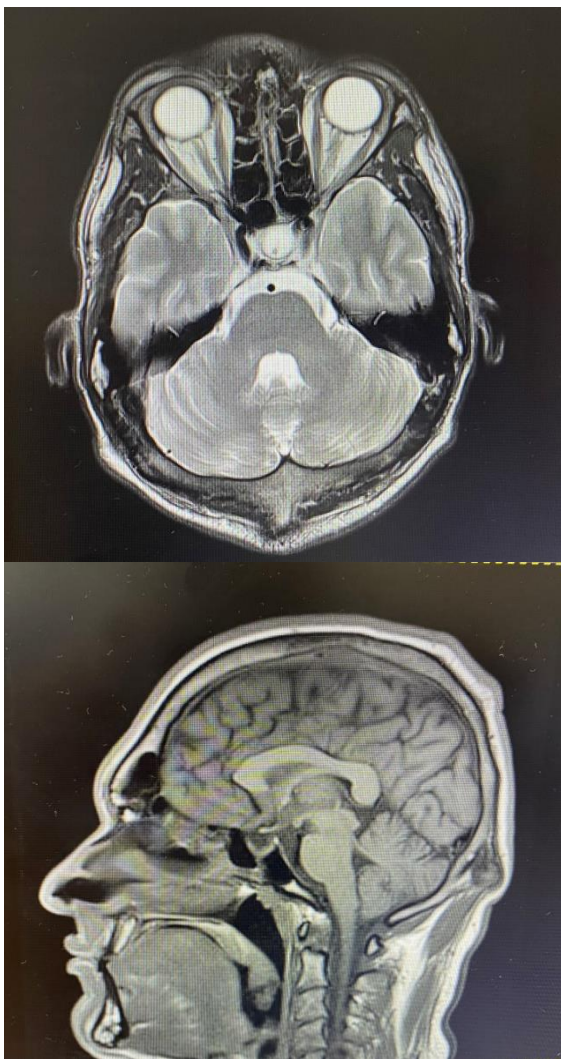
The patient underwent trans-sphenoidal hypophysectomy with favourable postoperative outcome. The hospitalization was for a few days, without peri-operative complications. The subject was discharged and had a good clinical evolution after surgery. The headache was remitted. Hystopathological and immunohistochemical examination confirmed the diagnostic of mammosomatotropic pituitary adenoma apoplexy that displayed 85% of the tumor volume (Table 10).

At follow-up, after 3 months, normal glycaemic status was observed (Table 1), thus GH in OGTT (oral glucose tolerance test) was performed, and GH suppression was detected (Table 8). The level of IGF1 was 167.6 ng/mL (normal ranges: 83-262) (Table 6). The endocrine panel included normal thyroid function (Table 2) and thyroid ultrasound without pathological changes (Figure 3) and morning plasma cortisol, testosterone and prolactin with levels within normal ranges (Tables 4 to 6).

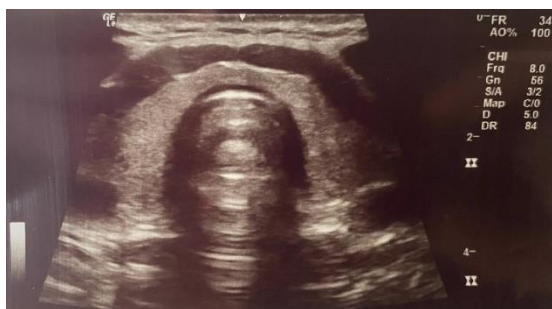

**Figure 1 - Preoperative MRI Transversal and sagittal plane reveal an inhomogenous pituitary tumor with hemorrhage and necrosis with maximum diameters of 15mm/12 mm/13 mm.**

IV contrast MRI revealed: hypophysis tumor ablation, without residual tumour tissue, postoperative empty sella, left frontal cyst of 12 mm, nasal septum deviation, normal optic chiasm and cavernous sinuses, low neurohypophyseal T1 signal and right posterior clinoid apophysis, adipose tissue with micronodular aspect of 4/4.7 mm, adenohypophysis at the level of sella turcica (Figure 2). Based on the endocrine exam following the neurosurgical procedure, the acromegaly was remitted, either due to apoplexy, either due to hypophysectomy, or both.



**Figure 2 - Three months later MRI scan described hypophyseal tumor ablation, without residual tumoral tissue, postoperative empty sella**



**Figure 3 - Thyroid ultrasound: Right thyroid lobe: 2/1.78/4.22cm, isthmus: 0.4cm, Left thyroid lobe:2/1.8/3.86cm, Echostructure: isoechoic, fine granular, low Doppler signal, laterocervical region: inflammatory polyadenopathies.**

## Discussion

This male case points out a form of life-threatening complication, namely pituitary apoplexy, involving a somatotropinoma. Surgical approach represents the management of choice in most of the cases, especially with large tumours in order to provide the best outcome [1,2]. In the meantime, in cases with headache symptomatic medication is provided while life-threatening acute adrenal insufficiency of central cause requires glucocorticoids substitution. A part from being an emergency, pituitary apoplexy is still a challenging situation due to its recognition because the patient might be apparently healthy, without a prior diagnostic of an endocrine tumour or a genetic syndrome like multiple endocrine neoplasia that increases the risk of an having a pituitary adenoma [2,5].

This report describes a patient with acromegalic clinical features and pituitary tumour apoplexy, an infrequent disease which requires a multidisciplinary team. A review of his photographs indicated changes in appearance starting 5 years ago, at the age of 21. His height was similar to the genetic potential height. The patient has no family history of acromegaly. Considering that this is a case of a young patient with a rare condition, genetic testing would be useful. The genetic panel should take into consideration AIP, menin mutations, etc. [8].

Pituitary apoplexy is a rare clinical occurrence [9]. The cause of tumour apoplexy remains debatable. Due to its large size, one possible cause of tumour apoplexy could be vascular compression. Another possible cause to be taken into account is previously undiagnosed diabetes mellitus, or the interaction of them both [10].

Surgical treatment was performed not only to prevent recurrence, but also to ensure decompression of the healthy remaining adenohypophysis.

Even though adrenal insufficiency remains uncertain, due to the low prolactin level, there should still be a high suspicion of ACTH deficiency. Considering that the patient denied an ITT, close monitoring of haemodynamic status is necessary, especially during infection, events causing low vascular volume and other stress periods.

### Conclusion

A young, previously healthy patient presented for headache which led to the discovery of an underlying pituitary adenoma apoplexy. In our patient's case, clinical acromegalic features, laboratory results suggestive of central hypothyroidism and hypogonadism and adrenal evaluation which could not rule out insufficiency are notable. Imagistic and histopathological examination diagnosed pituitary tumour apoplexy, a rare event that can explain laboratory findings such as moderately increased IGF1 with uncharacteristically normal GH levels in 24 hours GH profile. This illustrates the complex effects of pituitary tumour apoplexy. In addition, it is worth mentioning that following surgical treatment, IGF1 levels and glycaemic status normalized and no pituitary insufficiency was found at 3 months follow-up. Our patient's case emphasizes the importance of rare pathologies such as pituitary tumour apoplexy in the differential diagnosis of severe headache in young otherwise healthy patients. This case highlights the importance of pituitary approach in pituitary apoplexy, an emergent complication with a life-threatening potential.

### Abbreviations

ACTH=adenocorticotrophic hormone  
ATG=Anti-thyroglobulin antibodies  
ATPO=anti-thyroid antibodies  
BMD=bone mass density  
BMI=body mass index  
BP= blood pressure

DXA=dual energy X-ray absorptiometry  
FSH=follicle stimulating hormone  
FT4=free levothyroxine  
GH=growth hormone  
HR=heart rate  
IGF1=insulin-like growth factor 1  
ITT=insulin tolerance test  
LH=luteinizing hormone  
MRI=magnetic resonance imaging  
NA=not available  
OGTT=oral glucose tolerance test  
PRL=prolactin  
T3=triiodothyronine  
TSH=Thyroid Stimulating Hormone

**Conflict of interest:** none

**Acknowledgment:** none

### References

- [1] S Alam, S Kubihal, A Goyal, VP Jyotsna. Spontaneous Remission of Acromegaly After Pituitary Apoplexy in a Middle-Aged Male. *Ochsner J.* 2021 Summer;21(2):194-199.
- [2] A Klimko, C Capatina. Pituitary Macroadenoma Presenting as Acromegaly and Subacute Pituitary Apoplexy: Case Report and Literature Review. *Cureus.* 2020 Aug 8;12(8):e9612.
- [3] E Sanz-Sapera, S Sarria-Estrada, F Arikan, B Biagetti. Acromegaly remission, SIADH and pituitary function recovery after macroadenoma apoplexy. *Endocrinol Diabetes Metab Case Rep.* 2019 Jul 15;2019(1):19-0057.
- [4] RC Zhang, YF Mu, J Dong, XQ Lin, DQ Geng. Complex effects of apoplexy secondary to pituitary adenoma. *Rev Neurosci.* 2017 Jan 1;28(1):59-64.
- [5] A Valea, M Carsote, C Ghervan, C Georgescu. Glycemic profile in patients with acromegaly treated with somatostatin analogue. *J Med Life.* 2015;8(Spec issue):79-83.
- [6] D Banerji, NK Das, S Sharma, Y Jindal, VK Jain, S Behari. Surgical management of acromegaly: Long term functional outcome

analysis and assessment of recurrent/residual disease. *Asian J Neurosurg.* 2016 Jul-Sep;11(3):261-7.

[7] SH Roerink, EJ van Lindert, AC van de Ven. Spontaneous remission of acromegaly and Cushing's disease following pituitary apoplexy: Two case reports. *Neth J Med.* 2015 Jun;73(5):242-6.

[8] V Puglisi, E Morini, F Biasini, L Vinciguerra, G Lanza, P Bramanti. Neurological Presentation of Giant Pituitary Tumour Apoplexy: Case Report and Literature

Review of a Rare but Life-Threatening Condition. *J Clin Med.* 2022 Mar 13;11(6):1581. doi: 10.3390/jcm11061581.

[9] MA Arnold, Revuelta JM Barbero, G Pradilla, SK Wise.

Pituitary Gland Surgical Emergencies: The Role of Endoscopic Intervention. *Otolaryngol Clin North Am.* 2022 Apr;55(2):397-410.

[10] M Drissi Oudghiri, I Motaib, S Elamari, S Laidi, A Chadli. Pituitary Apoplexy in Geriatric Patients: A Report of Four Cases. *Cureus.* 2021 Dec 10;13(12):e20318.